

Highly Efficient Maternal-Fetal Zika Virus Transmission in Pregnant Rhesus Macaques

Authors: Sydney M. Nguyen^{1†}, Kathleen M. Antony^{1†}, Dawn M. Dudley^{2†}, Sarah Kohn³, Heather A. Simmons⁵, Bryce Wolfe², M. Shahriar Salamat², Leandro B. C. Teixeira¹⁰, Gregory J. Wiesz⁴, Troy H. Thoong⁵, Matthew T. Aliota⁶, Andrea M. Weiler⁵, Gabrielle L. Barry⁵, Kim L. Weisgrau⁵, Logan J. Vosler⁵, Mariel S. Mohns², Meghan E. Breitbach², Laurel M. Stewart², Mustafa N. Rasheed², Christina M. Newman², Michael E. Graham², Oliver E. Wieben³, Patrick A. Turski³, Kevin M. Johnson³, Jennifer Post⁵, Jennifer M. Hayes⁵, Nancy Schultz-Darken⁵, Michele L. Schotzko⁵, Josh A. Eudailey⁷, Sallie R. Permar⁷, Eva G. Rakasz⁵, Emma L. Mohr⁸, Saverio Capuano III⁵, Alice F. Tarantal⁹, Jorge E. Osorio⁶, Shelby L. O'Connor², Thomas C. Friedrich^{5,6}, David H. O'Connor^{2,5}, and Thaddeus G. Golos^{1,4,5}.

Affiliations:

¹Department of Obstetrics and Gynecology, University of Wisconsin-Madison, Madison, USA

²Department of Pathology and Laboratory Medicine, University of Wisconsin-Madison, Madison, USA

³Department of Radiology, University of Wisconsin-Madison, Madison, USA

⁴Department of Comparative Biosciences, University of Wisconsin-Madison, Madison, USA

⁵Wisconsin National Primate Research Center, University of Wisconsin-Madison, Madison USA

⁶Department of Pathobiological Sciences, University of Wisconsin-Madison, Madison, USA

⁷Department of Pediatrics and Human Vaccine Institute, Duke University Medical Center, Durham, USA

⁸Department of Pediatrics, University of Wisconsin-Madison, Madison, USA

⁹Departments of Pediatrics and Cell Biology and Human Anatomy, University of California-Davis, California National Primate Research Center, Davis, USA

¹⁰School of Veterinary Medicine, University of Wisconsin-Madison, Madison, USA

†These authors contributed equally to this work.

*Correspondence and request for materials should be addressed to T.G.G. (email: golos@primate.wisc.edu).

1 **Abstract**

2 Infection with Zika virus (ZIKV) is associated with human congenital fetal anomalies. To model
3 fetal outcomes in nonhuman primates, we administered Asian-lineage ZIKV subcutaneously to
4 four pregnant rhesus macaques. While non-pregnant animals in a previous study contemporary
5 with the current report clear viremia within 10-12 days, maternal viremia was prolonged in 3 of 4
6 pregnancies. Fetal head growth velocity in the last month of gestation determined by ultrasound
7 assessment of head circumference was decreased in comparison with biparietal diameter and
8 femur length within each fetus, both within normal range. ZIKV RNA was detected in tissues
9 from all four fetuses at term cesarean section. In all pregnancies, neutrophilic infiltration was
10 present at the maternal-fetal interface (decidua, placenta, fetal membranes), in various fetal
11 tissues, and in fetal retina, choroid, and optic nerve (first trimester infection only). Consistent
12 vertical transmission in this primate model may provide a platform to assess risk factors and test
13 therapeutic interventions for interruption of fetal infection. The results may also suggest that
14 maternal-fetal ZIKV transmission in human pregnancy may be more frequent than currently
15 appreciated.

16

17 **Author summary**

18 Maternal ZIKV infection in pregnancy is associated with severe fetal anomalies, including
19 microcephaly. It has been shown that infection manifests differently in pregnancy than in the
20 non-pregnant state, with prolonged maternal viremia. ZIKV is spread by mosquitos and through
21 sexual contact and since its first detection in early 2015, has become endemic to the Americas.
22 While much has been learned from studying infected human pregnancies, there are still many
23 questions concerning transmission of ZIKV from mother to fetus. Investigating ZIKV infection

24 in non-human primates could help answer these questions due to similarities in the immune
25 system, and the tissues separating the fetus from the mother during pregnancy. Our study serves
26 to model ZIKV transmission in early and late pregnancy, as well as study the effects of this
27 infection on the fetus and mother at these different times in pregnancy. The data collected
28 provides an important insight on ZIKV in pregnancy where the pregnancies have been monitored
29 throughout the entire infection period until term, and suggests that vertical transmission may be
30 very efficient, although severe fetal outcomes are uncommon.

31

32 **Introduction**

33 Zika Virus (ZIKV; *Flaviviridae*, *Flavivirus*) is spread by *Aedes* mosquitoes [1, 2] and sexual
34 contact [3-9]. ZIKV, first detected in the Americas in early 2015, is now endemic. *In utero*
35 infection with ZIKV circulating in Oceania and the Americas has been associated with increased
36 incidence of fetal microcephaly [10, 11]. Fetal findings include placental calcifications, growth
37 restriction, arthrogryposis, severe central nervous system (CNS) malformations [11-16],
38 intraocular calcifications, cataracts [17, 18] and skeletal [19, 20], and sensory [20] disorders. The
39 constellation of developmental abnormalities observed following ZIKV infection during
40 pregnancy is termed “congenital Zika syndrome” [21-23]. Prolonged viremia (>14 days) during
41 pregnancy compared to nonpregnant individuals (7-10 days [24]) has been noted [24-26];
42 however, the potential association between prolonged maternal viremia and congenital Zika
43 syndrome is not clear at this time.

44

45 Nonhuman primates are important models for human infectious disease, and ZIKV infection in
46 rhesus macaques (*Macaca mulatta*) has been established [27-29]. Viremia in nonpregnant Indian

47 rhesus macaques has been shown to persist for 7-10 days, similar to human infection [27-29].
48 Nonhuman primate pregnancy has salient similarities to human pregnancy, including
49 hemochorial placentation with extensive trophoblast invasion and remodeling of decidual spiral
50 arteries [30-32] and prolonged gestation with a similar trajectory of fetal development [33].
51 Maternal infection with a high dose (5000-fold higher than our current study) of an Asian viral
52 strain (strain FSS13025, Cambodia 2010) in a single pigtail macaque (*Macaca nemestrina*)
53 resulted in maternal viremia and severe fetal neurodevelopmental abnormalities as well as fetal
54 and placental infection [34].

55
56 It was previously reported that while moderate infectious doses of ZIKV are cleared promptly in
57 nonpregnant macaques, initial data from two pregnant macaques infected in the first trimester
58 showed prolonged viremia, similar to reports of human pregnancies [28]. Here we report that the
59 fetuses of these two first trimester ZIKV pregnancies, as well as two additional late second/early
60 third trimester infections, had maternal-fetal ZIKV transmission with vRNA and pathology in
61 fetal tissues as well as at the maternal-fetal interface.

62

63 **Results**

64 **Maternal ZIKV in blood and other body fluids**

65 Four pregnant macaques were infected by subcutaneous injection of 1×10^4 PFU of the Asian-
66 lineage ZIKV strain H.sapiens-tc/FRA/2013/FrenchPolynesia-01_v1c1 [28], which is closely
67 related to strains circulating in the Americas. Animals 827577 and 680875 were infected at 31 or
68 38 days gestation, respectively (mid-first trimester) (term 165 ± 10 days). Animals 598248 and
69 357676 were infected at 103 or 118 days gestation, respectively (late second/early third

70 trimester). ZIKV RNA was measured in plasma, urine, saliva, and amniotic fluid, and ultrasound
71 imaging of the fetus was performed following infection through ~155 days gestation (Figs. 1A,
72 S1). All monkeys had detectable plasma viremia for 11 to 70 days post-inoculation (dpi) (Figs.
73 1B, 2A) and at least one day of detectable vRNA in urine. Two macaques had detectable vRNA
74 in saliva, and one macaque infected at the beginning of the third trimester had detectable vRNA
75 in amniotic fluid on 15, 22, and 36 dpi (118, 125, and 139 days gestation, respectively) (Fig. 1B).

76

77 **Innate and adaptive immune responses to ZIKV**

78 The duration of viremia was prolonged in three of four pregnant macaques in comparison to non-
79 pregnant animals infected by the same route, dose, and strain of ZIKV in a previous study [28]
80 (Fig. 2A; compare colored and gray lines). Those animals were infected contemporaneously
81 (within 4 weeks) with the monkeys in the current study. To evaluate maternal immune responses,
82 peripheral blood CD16⁺ natural killer (NK) cell and CD95⁺CD28⁻ CD8 effector T cell
83 proliferation were monitored by flow cytometry for Ki-67 expression. Although responses were
84 variable, there was generally higher proliferation relative to baseline in peripheral blood CD16⁺
85 NK cells than in CD95⁺CD28⁻ CD8⁺ effector T cells (Fig. 2B), and these responses were not
86 qualitatively different from nonpregnant animals (Fig. 2B, grey tracings). The numbers of
87 circulating plasmablasts tended to increase more slowly in third-trimester infections; however,
88 the response did not distinctly differ between the first and third trimesters (Fig. 2C). Sera from
89 macaques that were infected with ZIKV in the first or third trimesters neutralized ZIKV-FP
90 across a range of serum dilutions. Indeed, neutralization curves prepared using sera from all 4
91 animals revealed a similar profile as compared to sera from ZIKV-infected nonpregnant animals
92 (Fig. 2D). All animals developed neutralizing antibodies (nAb) with a 90% plaque reduction

93 neutralizing antibody test (PRNT₉₀) titer of 1:160 (827577 and 598248) or 1:640 (660875 and
94 357676) by 28 dpi. Interestingly, animal 660875 (first trimester infection) had more vigorous and
95 prolonged NK, T cell, and plasmablast responses to infection compared to the other three
96 pregnancies. ZIKV infection was not associated with consistent changes in complete blood cell
97 counts or serum chemistry in pregnant animals (Fig. 3).

98

99 **Assessment of fetal growth**

100 Sonographic images (e.g., Fig. 4) were obtained approximately weekly to monitor fetal growth
101 and viability. No significant fetal or placental abnormalities were observed. Fetal femur length
102 (FL) was typically within one standard deviation (SD) of mean database values for fetal rhesus
103 macaques across gestation [35], suggesting absence of symmetrical growth restriction (Fig. 4A).
104 The biparietal diameter (BPD) was within two SD of expected values across gestation (Fig. 4B).
105 However, during the last month of pregnancy, head circumference (HC) in all animals was
106 between one and three SD below the mean (Fig. 4C).

107

108 To discern changes in fetal growth trajectories, we extrapolated the predicted gestational ages
109 (pGA) by mapping the observed fetal biometric measures in individual pregnancies onto
110 normative growth curves for BPD, FL, and HC [35, 36]. Figs. 5A-D compare within each animal
111 the pGA estimated by an average of BPD and FL with that estimated by HC. In 3 of 4
112 pregnancies, pGA as estimated by HC lagged 16.5 to 19 days behind the pGA estimated by an
113 average of BPD and FL. HC reflects both BPD and occipitofrontal diameters. Human fetuses and
114 infants affected by severe microcephaly in congenital ZIKV infection have vermis agenesis
115 (growth failure of the cerebellum) and reduced frontal cortex growth [11, 15, 18, 37]: regions of

116 the brain where growth deficits will give rise to a reduced occipitofrontal diameter. Fetal
117 Magnetic Resonance Imaging (MRI) was also performed for the dams infected in the first
118 trimester (827577, imaged at 102 dpi [140 days gestation], and 660875, imaged at 60 dpi [91
119 days gestation]). These images provided evidence of normal volume, cortical thickness,
120 sulcation, and ventricular and extra-axial spaces (Supplementary Fig. S2). However, it has been
121 reported that human infants whose mothers were infected with ZIKV during pregnancy have
122 been born with normal cranial anatomy, but developed microcephaly within 6 months [19, 38].
123 Thus, further studies focused on macaque postnatal development are warranted.

124

125 **Fetal viral burden and histopathology**

126 All ZIKV pregnancies progressed without overt adverse outcomes. At 153-158 days gestation,
127 fetuses were surgically delivered, euthanized, and tissues collected. None of the fetuses had
128 evidence of microcephaly or other abnormalities upon gross examination. Approximately 50
129 fetal and maternal tissues (Supplementary Fig. S3) were collected from each pregnancy for
130 histopathology and vRNA by qRT-PCR. Results are summarized in Fig 6. ZIKV RNA was
131 detected in all four fetuses, albeit in different tissues in individual fetuses, and in some maternal
132 tissues including spleen, liver, lymph node, and decidua (Fig. 6A). Notably, the pregnancy with
133 the longest duration of viremia (827577; 70 days viremia (39-109 days gestation) had fetal
134 tissues (optic nerve, axillary lymph node) with the highest vRNA burden. However, the fetus
135 from the short (9 day) duration maternal viremia (119-127 days gestation) also had vRNA in
136 fetal lymph node, pericardium, and lung (Fig. 6A).

137

138 Pathologists were blinded to vRNA and trimester of infection findings for histology evaluation

139 and scoring (Fig. 6B; see Supplementary Data S1 for a full listing of pathology findings). The
140 maternal-fetal interface in all four ZIKV infections presented minimal to moderate suppurative
141 placentitis with variable mineralization and necrosis, as well as minimal to moderate suppurative
142 deciduitis (Fig. 7). Three of four pregnancies had suppurative amnionitis and three of four dams
143 had mild to moderate suppurative splenitis. Histology confirmed normal CNS structures and
144 absence of encephalitis (inflammation) in all four fetuses. Morphologic fetal diagnoses included:
145 suppurative splenitis, suppurative to lymphoplasmacytic hepatitis, suppurative alveolitis
146 (pneumonia), and suppurative lymphadenitis (Supplementary Data S1). The duration of viremia
147 or trimester of maternal infection did not generally correlate with the severity or distribution of
148 scored fetal pathologies (Table 1), however it is significant that both fetuses infected during the
149 first trimester, but not the third trimester, had ocular pathology: inflammation of retina, choroid,
150 and optic nerve (Fig. 8, Supplementary Data S1). A segment of the fetal axillary lymph node
151 with the highest vRNA burden was immunostained for ZIKV. ZIKV NS2B-positive cells were
152 observed in lymph node medullary cords, a subset of which were CD163-positive macrophages
153 (Fig. 9).

154

155 **Discussion**

156 This study demonstrates that similar to human pregnancy, Indian rhesus macaque fetuses are
157 susceptible to congenital infection following maternal subcutaneous infection with a moderate
158 infectious dose of Asian-lineage ZIKV during the first or late second/early third trimesters.
159 Maternal-fetal transmission in the rhesus macaque is highly efficient: 4 of 4 maternal infections
160 resulted in infected fetuses, and all pregnancies demonstrated pathology at the maternal-fetal
161 interface and in the fetus, with variable fetal vRNA distribution. Fetal infection was

162 accompanied by an apparent reduced trajectory of fetal HC in the last month of gestation,
163 without overall fetal growth restriction. While we hypothesize that the duration of maternal
164 viremia correlates with risk for fetal impact, pathology at the maternal-fetal interface and fetal
165 vRNA in the pregnancy with the shortest duration of viremia following third trimester infection
166 suggests that the fetus is at risk even with a brief exposure to circulating maternal virus, as
167 reported in human pregnancy [12]. Indeed, our findings are consistent with the emerging picture
168 of congenital Zika syndrome, in which microcephaly is the most severe of a range of potential
169 sequelae. Given the high rate of vertical transmission in our model in the absence of severe
170 developmental defects, it seems possible that there is a higher rate of human fetal *in utero* ZIKV
171 exposure than is currently appreciated, exposures which do not result in malformations obvious
172 at birth, but may manifest later in postnatal development.

173
174 Models of vertical ZIKV transmission have been developed in mice [39, 40, 41, 42]. Mice are
175 generally not susceptible to ZIKV infection because ZIKV cannot subvert the interferon response
176 in mice as it does in humans [43]. However, studies have now been conducted with mouse
177 strains carrying deletions of the IFNAR or pattern recognition receptor genes (e.g., IRF3, IRF7)
178 [40, 41]. In these models, placental infection and pathology is revealed, and there is maternal-
179 fetal transmission and fetal growth defects, loss and brain injury [39, 40, 41]. More recently, an
180 alternate approach in which virus is directly injected into the uterine wall adjacent to the
181 conceptuses has been reported in immunocompetent mice, and this model also results in
182 placental infection and transmission of the virus to the fetus [42]. However, neither
183 immunodeficient nor uterine injection models are directly relevant to the mode of transmission
184 by which the human fetus is exposed to ZIKV. While murine genetic models allow mechanistic

185 investigation of ZIKV pathophysiology that cannot be explored with samples from human
186 clinical patients, the murine maternal-fetal interface, placental structure, and pace and
187 complexity of fetal brain development are quite different from humans, whereas nonhuman
188 primate pregnancy is very similar to human pregnancy in these critical areas for understanding
189 the impact of ZIKV on the fetus.

190

191 The NHP has previously been used to model TORCH infections (e.g., cytomegalovirus,
192 toxoplasma) on fetal infection and neuropathology [44-46], and listeriosis and other bacterial
193 infections on fetal loss and stillbirth [47, 48] and preterm labor [49]. Congenital ZIKV infection
194 in macaques provides a tractable and translational model of human disease. While it has
195 previously been reported that infection of a pregnant pigtail macaque with a Cambodian ZIKV
196 strain resulted in severe fetal malformations of the central nervous system [34], we did not
197 observe this outcome in our study. It is theoretically possible that the lack of severe outcomes,
198 including microcephaly, in our study may be due to the use of a specific ZIKV strain or dose,
199 that rhesus monkeys, in general, are resistant to ZIKV-induced fetal neuropathology, or that there
200 is a difference in ZIKV susceptibility between the rhesus macaques in our study and the single
201 pigtail macaque used in the previous study. Regardless, lack of a severe outcome should not be
202 considered a limitation of our study, since it is also known that only a subset of human maternal
203 infections result in severe fetal outcomes [50], and our current study significantly expands the
204 data available regarding ZIKV infection in nonhuman primates. Modest fetal
205 neurodevelopmental outcomes with the model we have described in this current report may
206 provide an opportunity to further evaluate factors which foster severe fetal developmental
207 impact, such as co-infection or previous exposure to other pathogens, and support the

208 development of strategies to prevent maternal-fetal transmission and reduce fetal virus burden.
209 Further information on the ontogeny of fetal infection and distribution of virus in the fetus during
210 gestation using relevant animal models will be important to establish before consideration of
211 interventional strategies, such as maternal or fetal passive immunization [51] in pregnant women
212 presenting with symptoms of ZIKV infection.

213

214 **Methods**

215 **Experimental design**

216 Four pregnant rhesus macaques (*Macaca mulatta*) of Indian ancestry were infected
217 subcutaneously with 1×10^4 PFU ZIKV (Zika virus/H.sapiens-tc/FRA/2013/FrenchPolynesia-
218 01_v1c1) at 31, 38, 104, or 119 days gestation (term 165 ± 10 days). All macaques utilized in the
219 study were free of Macacine herpesvirus 1, Simian Retrovirus Type D (SRV), Simian T-
220 lymphotropic virus Type 1 (STLV), and Simian Immunodeficiency Virus as part of the Specific
221 Pathogen Free (SPF) colony at WNPRC.

222

223 **Ethics Statement**

224 The rhesus macaques used in this study were cared for by the staff at the Wisconsin National
225 Primate Research Center (WNPRC) according to regulations and guidelines of the University of
226 Wisconsin Institutional Animal Care and Use Committee, which approved this study (protocol
227 g005401) in accordance with recommendations of the Weatherall report and according to the
228 principles described in the National Research Council's Guide for the Care and Use of
229 Laboratory Animals. All animals were housed in enclosures with at least 4.3, 6.0, or 8.0 sq. ft. of
230 floor space, measuring 30, 32, or 36 inches high, and containing a tubular PVC or stainless steel

231 perch. Each individual enclosure was equipped with a horizontal or vertical sliding door, an
232 automatic water lixit, and a stainless steel feed hopper. All animals were fed using a nutritional
233 plan based on recommendations published by the National Research Council. Twice daily
234 macaques were fed a fixed formula, extruded dry diet (2050 Teklad Global 20% Protein Primate
235 Diet) with adequate carbohydrate, energy, fat, fiber (10%), mineral, protein, and vitamin content.
236 Dry diets were supplemented with fruits, vegetables, and other edible objects (e.g., nuts, cereals,
237 seed mixtures, yogurt, peanut butter, popcorn, marshmallows, etc.) to provide variety to the diet
238 and to inspire species-specific behaviors such as foraging. To further promote psychological
239 well-being, animals were provided with food enrichment, human-to-monkey interaction,
240 structural enrichment, and manipulanda. Environmental enrichment objects were selected to
241 minimize chances of pathogen transmission from one animal to another and from animals to care
242 staff. While on study, all animals were evaluated by trained animal care staff at least twice each
243 day for signs of pain, distress, and illness by observing appetite, stool quality, activity level,
244 physical condition. Animals exhibiting abnormal presentation for any of these clinical
245 parameters were provided appropriate care by attending veterinarians. Prior to all minor/brief
246 experimental procedures, animals were sedated using ketamine anesthesia, which was reversed at
247 the conclusion of a procedure using atipamizole. Animals undergoing surgical delivery of fetuses
248 were pre-medicated with ketamine and general anesthesia was maintained during the course of
249 the procedure with isoflurane gas using an endotracheal tube. Animals were monitored regularly
250 until fully recovered from anesthesia. Delivered fetuses were anesthetized with ketamine, and
251 then euthanized by an intramuscular or intraperitoneal overdose injection of sodium
252 pentobarbital. Adult animals were not euthanized as part of these studies.

253

254 **Care and use of macaques**

255 Female monkeys were co-housed with compatible males and observed daily for menses and
256 breeding. Pregnancy was detected by ultrasound examination of the uterus at approximately 20-
257 24 days gestation following the predicted day of ovulation. The day of gestation was estimated
258 (+/- 2 days) based on the dams menstrual cycle and previous pregnancy history, observation of
259 copulation, and the greatest length of the fetus at initial ultrasound examination which was
260 compared to normative growth data in this species [35]. Ultrasound examination of the conceptus
261 was performed subsequent to ZIKV infection as described below. For all procedures (i.e.,
262 physical examinations, virus inoculations, ultrasound examinations, blood and swab collection),
263 animals were anesthetized with an intramuscular dose of ketamine (10 mg/kg). Blood samples
264 from the femoral or saphenous vein were obtained using a vacutainer system or needle and
265 syringe. The four pregnant macaques were monitored daily prior to and after infection for any
266 physical signs (e.g., diarrhea, inappetance, inactivity, atypical behaviors).

267

268 **Inoculations**

269 Zika virus/H.sapiens-tc/FRA/2013/FrenchPolynesia-01_v1c1, originally isolated from a 51-year-
270 old female in France returning from French Polynesia with a single round of amplification on
271 Vero cells, was obtained from Xavier de Lamballerie (European Virus Archive, Marseille
272 France). The inoculating stock was prepared and validated as previously described [28]. A
273 single harvest of virus with a titer of 1.26×10^6 PFU/mL (equivalent to 1.43×10^9 vRNA
274 copies/mL) was used for all 4 challenges. Animals were anesthetized as described above, and 1
275 mL of inocula was administered subcutaneously over the cranial dorsum. Post-inoculation,
276 animals were closely monitored by veterinary and animal care staff for adverse reactions or any

277 signs of disease.

278

279 **Immunophenotyping**

280 The number of activated/proliferating peripheral blood lymphocyte subset cells was quantified
281 using a modified version of our protocol detailed step-by-step in OMIP-028 [52] as previously
282 reported [28]. Briefly, 0.1 mL of EDTA-anticoagulated whole blood samples were incubated for
283 15 min at room temperature in the presence of a mastermix of antibodies against CD45 (clone
284 D058-1283, Brilliant Violet 786 conjugate, 2.5 μ l), CD3 (clone SP34-2 Alexa Fluor 700
285 conjugate, 5 μ l), CD8 (clone SK2, Brilliant Violet 510, 2.5 μ l), NKG2A/C (clone Z199, PE-Cy7
286 conjugate, 5 μ l), CD16 (clone 3G8, Pacific Blue conjugate, 5 μ l), CD69 (clone TP1.55.3, ECD
287 conjugate, 3 μ l), HLA-DR (clone 1D11, Brilliant Violet 650 conjugate, 1 μ l), CD4 (clone SK3,
288 Brilliant Violet 711 conjugate, 5 μ l), CD28 (clone CD28.2, PE conjugate, 5 μ l), and CD95 (clone
289 DX2, PE-Cy5 conjugate, 10 μ l) antigens. All antibodies were obtained from BD BioSciences,
290 with the exception of the NKG2A/C-specific antibody, which was purchased from Beckman
291 Coulter, and the CCR7 antibody that was purchased from R&D Systems. The cells were
292 permeabilized using Bulk Permeabilization Reagent (Life Technology), then stained for 15 min
293 with Ki-67 (clone B56, Alexa Fluor 647 conjugate) while the permeabilizer was present. The
294 cells were then washed twice in media and resuspended in 0.125 ml of 2% paraformaldehyde
295 until they were run on a BD LSRII Flow Cytometer. Flow data were analyzed using Flowjo
296 software version 9.9.3.

297

298 **Plasmablast detection**

299 Peripheral blood mononuclear cells (PBMCs) isolated from four ZIKV-infected pregnant rhesus

300 monkeys at 3, 7, 11, and 14 dpi were stained with the following panel of fluorescently labeled
301 antibodies (Abs) specific for the following surface markers to analyze for plasmablast presence:
302 CD20 FITC (L27), CD80 PE (L307.4), CD123 PE-Cy7(7G3), CD3 APC-Cy7 (SP34-2), IgG
303 BV605 (G18-145) (all from BD Biosciences, San Jose, CA), CD14 AF700 (M5E2), CD11c
304 BV421 (3.9), CD16 BV570 (3G8), CD27 BV650(O323) (all from BioLegend, San Diego, CA),
305 IgD AF647 (polyclonal) (Southern Biotech, Birmingham, AL), and HLA-DR PE-TxRed (TÜ36)
306 (Invitrogen, Carlsbad, CA). LIVE/DEAD Fixable Aqua Dead Cell Stain Kit (Invitrogen,
307 Carlsbad, CA) was used to discriminate live cells. Cells were analyzed exactly as previously
308 described [28].

309

310 **Complete blood count (CBC) and serum chemistry panels**

311 CBCs with white blood cell (WBC) differential counts were performed on EDTA-anticoagulated
312 whole blood samples on a Sysmex XS-1000i automated hematology analyzer (Sysmex
313 Corporation, Kobe, Japan). CBCs included the following tests: absolute WBC count, absolute
314 counts and percentages for WBC differentials, red blood cell (RBC) count, hemoglobin and
315 hematocrit, RBC indices (mean corpuscular volume, mean corpuscular hemoglobin, mean
316 corpuscular hemoglobin concentration, and red blood cell distribution width), platelet count, and
317 mean platelet volume. Blood smears were prepared and stained with Wright-Giemsa stain
318 (Wescor Aerospray Hematology Slide Stainer; Wescor Inc, Logan, UT). Manual slide
319 evaluations were performed on samples when laboratory-defined criteria were met (absolute
320 WBC count, WBC differential percentages, hemoglobin, hematocrit, or platelet count outside of
321 reference intervals; automated WBC differential counts unreported by the analyzer; and the
322 presence of analyzer-generated abnormal flags). Manual slide evaluations included WBC

323 differential and platelet counts with evaluation of WBC, RBC, and platelet morphologies.

324

325 Chemistry panels composed of 20 tests were performed on serum using a Cobas 6000 analyzer
326 (Roche Diagnostics, Risch-Rotkreuz, Switzerland). Tests in each panel included glucose, blood
327 urea nitrogen, creatinine, creatine kinase, cholesterol, triglycerides, aspartate aminotransferase,
328 alanine aminotransferase, lactic acid dehydrogenase, total bilirubin, gamma-glutamyl transferase,
329 total protein, albumin, alkaline phosphatase, calcium, phosphorous, iron, sodium, potassium, and
330 chloride. CBC and serum chemistry panel results were recorded in the WNPRC Electronic
331 Health Record (EHR) system with species, age, and sex-specific reference intervals provided
332 within the reports generated through the EHR.

333

334 **Plaque reduction neutralization test (PRNT90)**

335 Macaque serum samples were screened for ZIKV neutralizing antibodies utilizing a plaque
336 reduction neutralization test (PRNT) on Vero cells (ATCC #CCL-81). Endpoint titrations of
337 reactive sera, utilizing a 90% cutoff (PRNT90) were performed as previously reported [28, 53]
338 against ZIKV strain H.sapiens-tc/FRA/2013/FrenchPolynesia-01_v1c1 [28]. Briefly, ZIKV was
339 mixed with serial 2-fold dilutions of serum for 1 hour at 37°C prior to being added to Vero cells
340 and neutralization curves were generated using GraphPad Prism software. The resulting data
341 were analyzed by non-linear regression to estimate the dilution of serum required to inhibit both
342 90% and 50% of infection.

343

344 **Fetal Rhesus Biometric Measurements**

345 Dams were sedated with ketamine hydrochloride (10 mg/kg) for sonographic assessments and

346 amniocentesis. The biparietal diameter (BPD) and head circumference (HC) were measured on
347 an axial image at the level of the hypoechoic thalami, with the echogenic interhemispheric
348 fissure/falx all well visualized [54, 55]. The BPD was measured from the outer margin of the
349 near calvarial echo to the inner margin of the deep calvarial echo. The HC was measured
350 circumferentially at the outer margin of the calvaria [55-57]. The abdominal circumference was
351 measured on an axial plane at the level of the stomach and the bifurcation of the main portal vein
352 into the left and right branches, approximately perpendicular to the spine; the abdominal
353 circumference was measured around the outside of the margin of the fetal abdomen [55, 58].
354 The femur length (FL) was measured from the greater trochanter to the lateral condyle along the
355 distal end of the shaft, excluding the femoral head and the distal epiphysis [57]. Growth curves
356 were developed [55] for ZIKV-infected monkeys for BPD, HC, and FL. Mean measurements and
357 standard deviations at specified days of gestation in Rhesus macaques were retrieved from
358 Tarantal [35].

359

360 **Fetal Rhesus Amniocentesis**

361 Under real-time ultrasound guidance, a 22 gauge, 3.5 inch Quincke spinal needle was inserted
362 into the amniotic sac. After 1.5-2 mL of fluid were removed and discarded due to potential
363 maternal contamination, an additional 3-4 mL of amniotic fluid were removed for viral qRT-
364 PCR analysis as described elsewhere [28]. These samples were obtained at the gestational ages
365 specified in Fig. 1A. All fluids were free of any blood contamination.

366

367 **Magnetic Resonance Imaging**

368 Noninvasive imaging of the fetal brain was performed on isoflurane-anesthetized monkeys on a

369 clinical 3T Magnetic Resonance Imaging (MRI) system (MR750, GE Healthcare, Waukesha,
370 WI). T1 and T2-weighted axial and sagittal images were acquired. T2-weighted axial images
371 were acquired with a single shot fast spin echo (SSFSE) sequence. Scan protocol for
372 Supplementary Fig. S2A: respiratory gated multislice 2D acquisition; TE/TR = 141 / 2526 ms;
373 Slice thickness: 2 mm; acquired spatial resolution = 1.25 mm x 1.25 mm; receiver bandwidth =
374 651 Hz/pixel. For Supplementary Fig. S2B, T1-weighted axial images were acquired with a
375 multiecho spoiled gradient echo sequence. The scan protocol for respiratory gated 3D acquisition
376 under isoflurane anesthesia was iterative decomposition with echo asymmetry and least-squares
377 estimation (IDEAL) processing for reconstruction of in-phase images from 8 echoes; 2 shots, 4
378 echoes each shot; flip angle = 15 deg; TE min = 1.6 ms; TR = 15.4 ms; Slice thickness: 1 mm;
379 acquired spatial resolution = 1.1 mm x 1.1 mm; receiver bandwidth = 488 Hz/pixel. Animals
380 were intubated for anesthesia under ketamine sedation, and imaging sessions lasted for
381 approximately 1 hour.

382

383 **Viral RNA isolation from urine, amniotic fluid, and oral/vaginal swabs**

384 RNA was isolated from maternal and fetal plasma and PBMC, urine, amniotic fluid, and oral and
385 vaginal swabs using the Viral Total Nucleic Acid Purification Kit (Promega, Madison, WI) on a
386 Maxwell 16 MDx instrument as previously reported [28].

387

388 **Viral RNA isolation from fetal and maternal tissues**

389 Fetal and maternal tissues were processed with RNeasy (Invitrogen, Carlsbad, CA) according
390 to the manufacturer protocols. Viral RNA was isolated from the tissues using the Maxwell 16
391 LEV simplyRNA Tissue Kit (Promega, Madison, WI) on a Maxwell 16 MDx instrument

392 (Promega, Madison, WI). A range of 20-40 mg of each tissue was homogenized using
393 homogenization buffer from the Maxwell 16 LEV simplyRNA Tissue Kit, the TissueLyser
394 (Qiagen, Hilden, Germany) and two 5 mm stainless steel beads (Qiagen, Hilden, Germany) in a 2
395 ml snapcap tube, shaking twice for 3 minutes at 20 Hz each side. The isolation was continued
396 according to the Maxwell 16 LEV simplyRNA Tissue Kit protocol, and samples were eluted into
397 50 μ l RNase free water.

398

399 **Quantitative reverse transcription PCR (qRT-PCR)**

400 Viral RNA isolated from plasma, urine, oral swabs, amniotic fluid, and maternal or fetal tissues
401 was quantified by qRT-PCR using modified primers and probe adapted from Lanciotti *et al.* [59]
402 as previously described [53]. The SuperScript III Platinum one-step quantitative RT-PCR system
403 was used (Invitrogen, Carlsbad, CA) on the LightCycler 480 instrument (Roche Diagnostics,
404 Indianapolis, IN). Assay probes were used at final concentrations of 600 nM and 100 nM
405 respectively, along with 150 ng random primers (Promega, Madison, WI). Conditions and
406 methods were as previously described [28]. Tissue viral loads were calculated per mg of tissue.

407

408 **Cesarean Section and Tissue Collection (Necropsy)**

409 At ~155 days gestation, fetal and maternal tissues were surgically removed at laparotomy. These
410 were survival surgeries for the dams. The entire conceptus within the gestational sac (fetus,
411 placenta, fetal membranes, umbilical cord, and amniotic fluid) was collected and submitted for
412 necropsy. The fetus was euthanized with an overdose of sodium pentobarbitol (50 mg/kg).
413 Tissues were carefully dissected using sterile instruments that were changed between each organ
414 and tissue type to minimize possible cross contamination. Each organ/tissue was evaluated

415 grossly *in situ*, removed with sterile instruments, placed in a sterile culture dish, and sectioned
416 for histology, viral burden assay, or banked for future assays. Sampling priority for small or
417 limited fetal tissue volumes (e.g., thyroid gland, eyes) was vRNA followed by histopathology, so
418 not all tissues were available for both analyses. Sampling of all major organ systems and
419 associated biological samples included the CNS (brain, spinal cord, eyes), digestive, urogenital,
420 endocrine, musculoskeletal, cardiovascular, hematopoietic, and respiratory systems as well as
421 amniotic fluid, gastric fluid, bile, and urine. A comprehensive listing of all specific tissues
422 collected and analyzed is presented in Fig. 6 and Supplementary Fig. S3.

423

424 Biopsies of the placental bed (uterine placental attachment site containing deep decidua basalis
425 and myometrium), maternal liver, spleen, and a mesenteric lymph node were collected
426 aseptically during surgery into sterile petri dishes, weighed, and further processed for viral
427 burden and when sufficient sample size was obtained, histology. Maternal decidua was dissected
428 from the maternal surface of the placenta.

429

430 **Histology**

431 Tissues were fixed in 10% neutral buffered formalin for 14 days and transferred into 70%
432 ethanol until routinely processed and embedded in paraffin. Paraffin sections (5 μ m) were
433 stained with hematoxylin and eosin (H&E). Pathologists were blinded to vRNA findings when
434 tissue sections were evaluated microscopically. Lesions in each tissue were described and scored
435 for severity as shown in Fig. 6B, and assigned morphologic diagnoses assigned as listed in
436 Supplementary Data S1. Photomicrographs were obtained using a bright light microscope
437 Olympus BX43 and Olympus BX46 (Olympus Inc., Center Valley, PA) with attached Olympus

438 DP72 digital camera (Olympus Inc.) and Spot Flex 152 64 Mp camera (Spot Imaging), and
439 captured using commercially available image-analysis software (cellSens Dimension^R, Olympus
440 Inc. and spot software 5.2).

441
442 For immunohistochemistry, tissues were fixed in 4% paraformaldehyde/PBS overnight then
443 paraffin embedded. 5 μ m sections were cut and deparaffinized. Antigen retrieval was
444 accomplished by incubation in heated (95°C) 10 mM citrate buffer (pH 6.0) plus 0.05% Tween-
445 20. The sections were blocked with 5% normal donkey serum for 1 hour at room temp then
446 incubated overnight at 4°C with rabbit anti Zika NS2B 1:100 (GeneTex GTX133308, Irvine,
447 CA) and mouse anti-CD163 1:100 (Novus, NB110-40686, Littleton, CO) or comparable control
448 IgGs (Santa Cruz, Santa Cruz CA). Sections were rinsed with TBS + tween-20 (TBST) 3x and
449 incubated with the appropriate secondary antibodies; donkey anti-rabbit Alexa 647 (1:5000),
450 donkey anti-mouse Alexa 488 (1:2500) for 1 hour at room temperature (Jackson
451 ImmunoResearch Laboratories, West Grove, PA). Sections were washed (3x TBST), exposed to
452 DAPI and mounted with Aqua Poly Seal (Polysciences Inc, Warrington, PA). Sections were
453 evaluated on a Leica SP8 confocal microscope.

454

455 **Data availability**

456 Primary data that support the findings of this study are available at the Zika Open-Research
457 Portal (<https://zika.labkey.com>). Zika virus/H.sapiens-tc/FRA/2013/FrenchPolynesia-01_v1c1
458 sequence data have been deposited in the Sequence Read Archive (SRA) with accession code
459 SRP072852. The authors declare that all other data supporting the findings of this study are
460 available within the article and its supplementary information files.

461

462 **Acknowledgements**

463 We thank the WNPRC Veterinary, Scientific Protocol Implementation, and Pathology Services
464 staff for assistance with animal procedures, including breeding, ultrasound monitoring, and
465 sample collection, and Ms. Rebecca Black for editorial assistance. We thank Adam Ericson,
466 Jenna Kropp, and Jiro Wada for help in figure design and illustration.

467 **References**

- 468 1. Hahn MB, Eisen RJ, Eisen L, Boegler KA, Moore CG, McAllister J, et al. Reported
469 Distribution of *Aedes* (*Stegomyia*) *aegypti* and *Aedes* (*Stegomyia*) *albopictus* in the
470 United States, 1995-2016 (Diptera: Culicidae). *J Med Entomol*. 2016.
- 471 2. Musso D, Gubler DJ. Zika Virus. *Clin Microbiol Rev*. 2016;29(3):487-524.
- 472 3. Barzon L, Pacenti M, Franchin E, Lavezzo E, Trevisan M, Sgarabotto D, et al. Infection
473 dynamics in a traveller with persistent shedding of Zika virus RNA in semen for six
474 months after returning from Haiti to Italy, January 2016. *Euro Surveill*. 2016;21(32).
- 475 4. Brooks JT, Friedman A, Kachur RE, LaFlam M, Peters PJ, Jamieson DJ. Update: Interim
476 Guidance for Prevention of Sexual Transmission of Zika Virus - United States, July
477 2016. *MMWR Morb Mortal Wkly Rep*. 2016;65(29):745-7.
- 478 5. Davidson A, Slavinski S, Komoto K, Rakeman J, Weiss D. Suspected Female-to-Male
479 Sexual Transmission of Zika Virus - New York City, 2016. *MMWR Morb Mortal Wkly*
480 *Rep*. 2016;65(28):716-7.
- 481 6. Deckard DT, Chung WM, Brooks JT, Smith JC, Woldai S, Hennessey M, et al. Male-to-
482 Male Sexual Transmission of Zika Virus--Texas, January 2016. *MMWR Morb Mortal*
483 *Wkly Rep*. 2016;65(14):372-4.
- 484 7. Foy BD, Kobylinski KC, Chilson Foy JL, Blitvich BJ, Travassos da Rosa A, Haddow
485 AD, et al. Probable non-vector-borne transmission of Zika virus, Colorado, USA. *Emerg*
486 *Infect Dis*. 2011;17(5):880-2.
- 487 8. Hills SL, Russell K, Hennessey M, Williams C, Oster AM, Fischer M, et al.
488 Transmission of Zika Virus Through Sexual Contact with Travelers to Areas of Ongoing

- 489 Transmission - Continental United States, 2016. *MMWR Morb Mortal Wkly Rep.*
490 2016;65(8):215-6.
- 491 9. Rowland A, Washington CI, Sheffield JS, Pardo-Villamizar CA, Segars JH. Zika virus
492 infection in semen: a call to action and research. *J Assist Reprod Genet.* 2016;33(4):435-
493 7.
- 494 10. Cauchemez S, Besnard M, Bompard P, Dub T, Guillemette-Artur P, Eyrolle-Guignot D,
495 et al. Association between Zika virus and microcephaly in French Polynesia, 2013-15: a
496 retrospective study. *Lancet.* 2016;387(10033):2125-32.
- 497 11. Schuler-Faccini L, Ribeiro EM, Feitosa IM, Horovitz DD, Cavalcanti DP, Pessoa A, et al.
498 Possible Association Between Zika Virus Infection and Microcephaly - Brazil, 2015.
499 *MMWR Morb Mortal Wkly Rep.* 2016;65(3):59-62.
- 500 12. Brasil P, Pereira JP, Jr., Moreira ME, Ribeiro Nogueira RM, Damasceno L, Wakimoto
501 M, et al. Zika Virus Infection in Pregnant Women in Rio de Janeiro. *N Engl J Med.*
502 2016;375(24):2321-34.
- 503 13. Martines RB, Bhatnagar J, de Oliveira Ramos AM, Davi HP, Iglezias SD, Kanamura CT,
504 et al. Pathology of congenital Zika syndrome in Brazil: a case series. *Lancet.*
505 2016;388(10047):898-904.
- 506 14. Noronha L, Zanluca C, Azevedo ML, Luz KG, Santos CN. Zika virus damages the
507 human placental barrier and presents marked fetal neurotropism. *Mem Inst Oswaldo*
508 *Cruz.* 2016;111(5):287-93.
- 509 15. Oliveira Melo AS, Malinger G, Ximenes R, Szejnfeld PO, Alves Sampaio S, Bispo de
510 Filippis AM. Zika virus intrauterine infection causes fetal brain abnormality and
511 microcephaly: tip of the iceberg? *Ultrasound Obstet Gynecol.* 2016;47(1):6-7.

- 512 16. Soares de Oliveira-Szejnfeld P, Levine D, Melo AS, Amorim MM, Batista AG, Chimelli
513 L, et al. Congenital Brain Abnormalities and Zika Virus: What the Radiologist Can
514 Expect to See Prenatally and Postnatally. *Radiology*. 2016;281(1):203-18.
- 515 17. de Paula Freitas B, de Oliveira Dias JR, Prazeres J, Sacramento GA, Ko AI, Maia M, et
516 al. Ocular Findings in Infants With Microcephaly Associated With Presumed Zika Virus
517 Congenital Infection in Salvador, Brazil. *JAMA Ophthalmol*. 2016.
- 518 18. Moore CA, Staples JE, Dobyns WB, Pessoa A, Ventura CV, Fonseca EB, et al.
519 Characterizing the Pattern of Anomalies in Congenital Zika Syndrome for Pediatric
520 Clinicians. *JAMA Pediatr*. 2016.
- 521 19. van der Linden V, Filho EL, Lins OG, van der Linden A, Aragao Mde F, Brainer-Lima
522 AM, et al. Congenital Zika syndrome with arthrogryposis: retrospective case series study.
523 *BMJ*. 2016;354:i3899.
- 524 20. Leal MC, Muniz LF, Ferreira TS, Santos CM, Almeida LC, Van Der Linden V, et al.
525 Hearing Loss in Infants with Microcephaly and Evidence of Congenital Zika Virus
526 Infection - Brazil, November 2015-May 2016. *MMWR Morb Mortal Wkly Rep*.
527 2016;65(34):917-9.
- 528 21. Costello A, Dua T, Duran P, Gulmezoglu M, Oladapo OT, Perea W, et al. Defining the
529 syndrome associated with congenital Zika virus infection. *Bull World Health Organ*.
530 2016;94(6):406-A.
- 531 22. Franca GV, Schuler-Faccini L, Oliveira WK, Henriques CM, Carmo EH, Pedi VD, et al.
532 Congenital Zika virus syndrome in Brazil: a case series of the first 1501 livebirths with
533 complete investigation. *Lancet*. 2016;388(10047):891-7.

- 534 23. Miranda-Filho Dde B, Martelli CM, Ximenes RA, Araujo TV, Rocha MA, Ramos RC, et
535 al. Initial Description of the Presumed Congenital Zika Syndrome. *Am J Public Health*.
536 2016;106(4):598-600.
- 537 24. Meaney-Delman D, Oduyebo T, Polen KN, White JL, Bingham AM, Slavinski SA, et al.
538 Prolonged Detection of Zika Virus RNA in Pregnant Women. *Obstet Gynecol*.
539 2016;128(4):724-30.
- 540 25. Driggers RW, Ho CY, Korhonen EM, Kuivanen S, Jaaskelainen AJ, Smura T, et al. Zika
541 Virus Infection with Prolonged Maternal Viremia and Fetal Brain Abnormalities. *N Engl*
542 *J Med*. 2016.
- 543 26. van der Eijk AA, van Genderen PJ, Verdijk RM, Reusken CB, Mogling R, van Kampen
544 JJ, et al. Miscarriage Associated with Zika Virus Infection. *N Engl J Med*.
545 2016;375(10):1002-4.
- 546 27. Abbink P, Larocca RA, De La Barrera RA, Bricault CA, Moseley ET, Boyd M, et al.
547 Protective efficacy of multiple vaccine platforms against Zika virus challenge in rhesus
548 monkeys. *Science*. 2016;353(6304):1129-32.
- 549 28. Dudley DM, Aliota MT, Mohr EL, Weiler AM, Lehrer-Brey G, Weisgrau KL, et al. A
550 rhesus macaque model of Asian-lineage Zika virus infection. *Nat Commun*.
551 2016;7:12204.
- 552 29. Osuna CE, Lim SY, Deleage C, Griffin BD, Stein D, Schroeder LT, et al. Zika viral
553 dynamics and shedding in rhesus and cynomolgus macaques. *Nature medicine*.
554 2016;22(12):1448-55.

- 555 30. Blankenship TN, Enders AC, King BF. Trophoblastic invasion and the development of
556 uteroplacental arteries in the macaque: immunohistochemical localization of cytokeratins,
557 desmin, type IV collagen, laminin, and fibronectin. *Cell Tissue Res.* 1993;272(2):227-36.
- 558 31. Bondarenko GI, Burleigh DW, Durning M, Breburda EE, Grendell RL, Golos TG.
559 Passive immunization against the MHC class I molecule Mamu-AG disrupts rhesus
560 placental development and endometrial responses. *J Immunol.* 2007;179(12):8042-50.
- 561 32. Enders AC. Implantation in the macaque: expansion of the implantation site during the
562 first week of implantation. *Placenta.* 2007;28(8-9):794-802.
- 563 33. Adams Waldorf KM, Rubens CE, Gravett MG. Use of nonhuman primate models to
564 investigate mechanisms of infection-associated preterm birth. *BJOG.* 2011;118(2):136-
565 44.
- 566 34. Adams Waldorf KM, Stencel-Baerenwald JE, Kapur RP, Studholme C, Boldenow E,
567 Vornhagen J, et al. Fetal brain lesions after subcutaneous inoculation of Zika virus in a
568 pregnant nonhuman primate. *Nature medicine.* 2016;22(11):1256-9.
- 569 35. Tarantal AF. Ultrasound Imaging in Rhesus (*Macaca mulatta*) and Long-tailed (*Macaca*
570 *fascicularis*) Macaques: Reproductive and Research Applications. In: Wolfe-Coote S,
571 editor. *The Laboratory Primate.* London: Elsevier; 2005. p. 317-52.
- 572 36. Tarantal AF, Hendrickx AG. Prenatal Growth in the *Cynomolgus* and Rhesus Macaque (
573 *Macaca fascicularis* and *Macaca mulatta*): A Comparison by Ultrasonography. *American*
574 *journal of primatology.* 1988;15:309-23.
- 575 37. Mlakar J, Korva M, Tul N, Popovic M, Poljsak-Prijatelj M, Mraz J, et al. Zika Virus
576 Associated with Microcephaly. *N Engl J Med.* 2016;374(10):951-8.

- 577 38. van der Linden V, Pessoa A, Dobyns W, Barkovich AJ, Junior HV, Filho EL, et al.
578 Description of 13 Infants Born During October 2015-January 2016 With Congenital Zika
579 Virus Infection Without Microcephaly at Birth - Brazil. *MMWR Morb Mortal Wkly Rep.*
580 2016;65(47):1343-8.
- 581 39. Cugola FR, Fernandes IR, Russo FB, Freitas BC, Dias JL, Guimarães KP, et al. The
582 Brazilian Zika virus strain causes birth defects in experimental models. *Nature.*
583 2016;534(7606):267-71.
- 584 40. Miner JJ, Cao B, Govero J, Smith AM, Fernandez E, Cabrera OH, et al. Zika Virus infection
585 during pregnancy in mice causes placental damage and fetal demise. *Cell.*
586 2016;165(5):1081-91.
- 587 41. Yockey LJ, Varela L, Rakib T, Khoury-Hanold W, Fink SL, Stutz B, et al. Vaginal
588 exposure to Zika virus during pregnancy leads to fetal brain infection. *Cell.*
589 2016;166(5):1247-56.
- 590 42. Vermillion MS, Lei J, Shabi Y, Baxter VK, Crilly NP, McLane M, et al. Intrauterine Zika
591 virus infection of pregnant immunocompetent mice models transplacental transmission
592 and adverse perinatal outcomes. *Nat Commun.* 2017;8:14575.
- 593 43. Grant A, Ponia SS, Tripathi S, Balasubramaniam V, Miorin L, Sourisseau M, et al. Zika
594 virus targets human STAT2 to inhibit type I Interferon signaling. *Cell Host Microbe.*
595 2016;19(6):882-90.
- 596 44. Tarantal AF, Salamat MS, Britt WJ, Luciw PA, Hendrickx AG, and Barry PA.
597 Neuropathogenesis induced by rhesus cytomegalovirus in fetal rhesus monkeys (*Macaca*
598 *mulatta*). *J Infect Dis.* 1998;177(2):446-50.

- 599 45. Bialas KM, Tanaka T, Tran D, Varner V, Cisneros De La Rosa E, Chiuppesi F, et al.
600 Maternal CD4+ T cells protect against severe congenital cytomegalovirus disease in a
601 novel nonhuman primate model of placental cytomegalovirus transmission. *Proc Natl*
602 *Acad Sci U S A*. 2015;112(44):13645-50.
- 603 46. Schoondermark-van de Ven EM, Melchers WJ, Galama JM, Meuwissen JH, and Eskes TK.
604 Prenatal diagnosis and treatment of congenital *Toxoplasma gondii* infections: an
605 experimental study in rhesus monkeys. *Eur J Obstet Gynecol Reprod Biol*.
606 1997;77(2):183-8.
- 607 47. Smith MA, Takeuchi K, Anderson G, Ware GO, McClure HM, Raybourne RB, et al. Dose-
608 response model for *Listeria monocytogenes*-induced stillbirths in nonhuman primates.
609 *Infect Immun*. 2008;76(2):726-31.
- 610 48. Wolfe B, Wiepz GJ, Schotzko M, Bondarenko GI, Durning M, Simmons HA, et al. Acute
611 fetal demise with first trimester maternal infection resulting from *Listeria monocytogenes*
612 in a nonhuman primate model. *MBio*. 2017;8(1).
- 613 49. Adams Waldorf KM, Rubens CE, and Gravett MG. Use of nonhuman primate models to
614 investigate mechanisms of infection-associated preterm birth. *BJOG*. 2011;118(2):136-
615 44.
- 616 50. Reynolds MR, Jones AM, Petersen EE, Lee EH, Rice ME, Bingham A, et al. Vital Signs:
617 Update on Zika virus-associated birth defects and evaluation of all U.S. infants with
618 congenital Zika virus exposure - U.S. Zika Pregnancy Registry, 2016. *MMWR Morb*
619 *Mortal Wkly Rep*. 2017;66(13):366-73.

- 620 51. Juckstock J, Rothenburger M, Friese K, Traunmuller F. Passive Immunization against
621 Congenital Cytomegalovirus Infection: Current State of Knowledge. *Pharmacology*.
622 2015;95(5-6):209-17.
- 623 52. Pomplun N, Weisgrau KL, Evans DT, Rakasz EG. OMIP-028: Activation panel for
624 Rhesus macaque NK cell subsets. *Cytometry Part A*. 2015;87(10):890-3.
- 625 53. Aliota MT, Dudley DM, Newman CM, Mohr EL, Gellerup DD, Breitbach ME, et al.
626 Heterologous Protection against Asian Zika Virus Challenge in Rhesus Macaques. *PLoS*
627 *Negl Trop Dis*. 2016;10(12):e0005168.
- 628 54. Shepard M, Filly RA. A standardized plane for biparietal diameter measurement. *J*
629 *Ultrasound Med*. 1982;1(4):145-50.
- 630 55. Tarantal AF, Hendrickx AG. Use of ultrasound for early pregnancy detection in the
631 rhesus and cynomolgus macaque (*Macaca mulatta* and *Macaca fascicularis*). *J Med*
632 *Primatol*. 1988;17(2):105-12.
- 633 56. Altman DG, Chitty LS. New charts for ultrasound dating of pregnancy. *Ultrasound*
634 *Obstet Gynecol*. 1997;10(3):174-91.
- 635 57. Ville Y, Nyberg DA. Growth, Doppler, and Fetal Assessment. In: Nyberg DA, McGahan
636 JP, Pretorius DH, Pilu G, editors. *Diagnostic Imaging of Fetal Anomalies*. Philadelphia,
637 PA: Lippincott Williams & Wilkins; 2003. p. 32-4.
- 638 58. Deter RL, Harrist RB, Hadlock FP, Carpenter RJ. The use of ultrasound in the assessment
639 of normal fetal growth: a review. *J Clin Ultrasound*. 1981;9(9):481-93.
- 640 59. Lanciotti RS, Kosoy OL, Laven JJ, Velez JO, Lambert AJ, Johnson AJ, et al. Genetic and
641 serologic properties of Zika virus associated with an epidemic, Yap State, Micronesia,
642 2007. *Emerg Infect Dis*. 2008;14(8):1232-9.

643 **Figure Legends**

644

645 **Figure 1.** Study layout and viral RNA burden in pregnant rhesus fluids. **(A)** Schematic
646 representation of the timeline of infection, sampling for maternal viral burden, and experimental
647 cesarean section, for all animals in the study. Animals received a ZIKV challenge in the first or
648 late second/early third trimesters of pregnancy, and blood and other fluid samples were collected
649 according to the schedule indicated in detail in supplementary Fig. S1. **(B)** ZIKV viral load in
650 pregnant macaque fluids. Viral RNA loads (vRNA copies/ml) measured in plasma, urine, saliva,
651 and amniotic fluid presented individually for the four pregnant animals. The day post-inoculation
652 is indicated below each graph, and gestational age (days) for each animal is indicated above
653 (term = 165±10 days). Limit of assay quantification is 100 copies/mL. Limit of detection is 33
654 copies/mL. Colors for individual animals are continued through the rest of the Figures, including
655 the Supplementary Figures.

656

657 **Figure 2.** Maternal viral control and immune responses to ZIKV inoculation. **(A)** Peripheral
658 blood plasma viremia in pregnant macaques infected with ZIKV. Results are shown for animals
659 infected at 38 days gestation (animal 827577, dark blue), 31 days gestation (animal 660875, light
660 blue), 103 days gestation (animal 357676, red) or 118 days gestation (animal 598248, yellow).
661 The day of gestation is estimated +/- 2 days. Grey tracings represent viremia in
662 nonpregnant/male rhesus monkeys infected with the identical dose and strain of ZIKV in a
663 previous study [28]. The horizontal line indicates the quantitative limit of detection. **(B)**
664 Peripheral blood cell response to infection. Absolute numbers of Ki67+ NK cells (left) or
665 CD8+TEM cells (right) are presented as a percentage relative to baseline set at 100% (dashed

666 line), with first trimester and third trimester animals represented in the same colors as presented
667 in Fig. 1A. (C) Plasmablast expansion over time from each pregnant animal. The plasmablast
668 expansions of two nonpregnant animals from Dudley *et al* [28] are shown as grey lines. (D)
669 Neutralization by ZIKV immune sera from pregnant and nonpregnant ZIKV-infected macaques.
670 Immune sera from macaques infected with ZIKV in either the first trimester (dark or light blue),
671 third trimester (red or yellow), or nonpregnant contemporary controls (gray) from Dudley *et al*
672 [28] were tested for their capacity to neutralize ZIKV-FP. Infection was measured by plaque
673 reduction neutralization test (PRNT) and is expressed relative to the infectivity of ZIKV-FP in
674 the absence of serum. The concentration of sera indicated on the x-axis is expressed as \log_{10}
675 (dilution factor of serum). The EC90 and EC50, estimated by non-linear regression analysis, are
676 also indicated by a dashed line. Neutralization curves for each animal at 28 dpi are shown.

677

678 **Figure 3.** Complete blood counts (CBCs) and serum chemistries for pregnant macaques infected
679 with ZIKV. Animals were infected with 10^4 PFU of ZIKV. Animals infected in the first or third
680 trimesters are represented by color coding (A) as presented in Fig. 1. All animals had CBC
681 analysis performed on EDTA blood and chemistry analysis performed on serum at -7, -3, 0, 1-10
682 and additional indicated dpi. B. AST blood chemistries, C. ALT serum chemistries, D. CK serum
683 chemistries, E. WBC counts, F. % lymphocytes, G. red blood cell (RBC) counts.

684

685 **Figure 4.** Fetal growth following ZIKV infection. Growth curves of femur length (FL),
686 biparietal diameter (BPD), and head circumference (HC) obtained from fetal ultrasound images
687 throughout gestation are presented as individual lines or symbols with specific colors as in Fig.
688 1. (A) FL, (B) BPD (C) and HC were determined for the fetuses in this study and plotted against

689 data from Tarantal [35], which is presented as the mean (solid black line) and 1, 2, and 3
690 standard deviations from the mean as grey lines above and below the mean. The data from the
691 last month of pregnancy are also presented as a magnified view of the scatter of individual data
692 points on the right. Representative ultrasound images of FL, BPD, and HC are also shown at the
693 right.

694

695 **Figure 5.** Fetal growth as assessed by predicted gestational ages. The predicted gestational age
696 (pGA) as described by Tarantal [35] from each of the pregnancies is plotted against the actual
697 day of gestation estimated from breeding activity and animal menstrual records. The pGA was
698 derived from the average of BPD+FL (dashed lines), or the HC (solid lines). **A** (animal 827577)
699 and **B** (animal 660875), first trimester infection. **C** (animal 357676) and **D** (animal 598248), late
700 second/early third trimester infection.

701

702 **Figure 6.** Charts summarizing **(A)** ZIKV RNA copy numbers, and **(B)** histologic evaluation
703 and semiquantitative scoring of all normal and lesioned tissues, presenting all maternal and fetal
704 tissues analyzed. Keys for ZIKV RNA copy number burden per mg of tissue, and description of
705 histopathology scores (“Normal” to “Severe”) appear at the left. Animal numbers are color
706 coded as introduced in Fig. 1.

707

708 **Figure 7.** Maternal and fetal histopathology analyses: hematoxylin and eosin (H&E) staining of
709 selected tissues. Maternal spleen, 660875: increased neutrophils (arrows) throughout splenic
710 sinusoids. Maternal decidua, 827577: multifocal stromal, intravascular, and perivascular
711 inflammation (arrows). Placenta, 660875: moderate multifocal necrosis and loss of trophoblastic

712 epithelium (+) with viable and degenerative neutrophils (arrows) between villi (*) and
713 throughout the intervillous space. Chorionic membrane, 598248: diffuse suppurative
714 inflammation throughout the chorionic membrane (ch) with rare single neutrophils (arrows)
715 within the overlying amnion. Amniotic membrane, 598248: scattered neutrophils within the
716 amniotic basement membrane and underlying perivascular stroma. Umbilical cord, 660875:
717 segmental thrombosis (*) with entrapped neutrophils (arrows). Fetal lung, 660875: fetal
718 squamous cells (*) and neutrophils (arrows) admixed with fibrin within alveolar spaces.

719

720 **Figure 8.** H&E Staining of fetal tissues of the visual system. **Panels 1A-C, animal 660875.**

721 Panel 1A: Mild infiltration of lymphocytes in the bulbar conjunctival substantia propria (arrow).

722 Panel 1B: Moderate neutrophilic infiltration in the ciliary body stroma (arrows). Panel 1C:

723 Moderate gliosis of the laminar and post-laminar optic nerve characterized by overall

724 hypercellularity of the neuropil especially as indicated by asterisks. **Panels 2A-C,**

725 **animal 827577.** Panel 2A: Minimal infiltration of lymphocytes in the bulbar conjunctival

726 substantia propria (arrows). Panel 2B: Normal ciliary body stroma. Panel 2C: Moderate gliosis of

727 the laminar and post-laminar optic nerve characterized by overall hypercellularity of the neuropil

728 especially as indicated by asterisks. **Panels 3A-C, animal 357676, and Panels 4A-C,**

729 **animal 598248.** Panels 3A and 4A: Normal bulbar conjunctival substantia propria. Panels 3B

730 and 4B: Normal ciliary body stroma. Panels 3C and 4C: Normal optic nerve.

731

732 **Figure 9.** Immunohistochemical localization of ZIKV in fetal [and maternal] tissues. **(A)**

733 Immunofluorescent staining for ZIKV NS2B (red) and macrophage marker CD163 (green) in

734 fetal axillary lymph node with a high vRNA burden. The white scale bar = 100 μ m. **(B)** H&E

735 stained near section of the tissue presented in 9A. (C) Nonspecific immunostaining with control
736 isotypes for ZIKV NS2B and CD163.

737 **Table 1. Summary of maternal observations and maternal and fetal pathology and vRNA burden.**

ID	Trimester of infection	duration of viremia (days)	Peak plasma viremia	Amn. Fluid*	Saliva	Difference in BPD+FL vs. HC (days)	Score of maternal path	Score of maternal RNA*	Score of MFI path	MFI RNA *	Fetal path	Fetal RNA *	Fetal ocular path
598248	3	11	17,400	0	-	16.5	0	6	7	1	11	6	0
357676	3	28	329,000	4	+	18.5	2	2	12	7	2	0	0
827577	1	71	668,000	0	+	19	2	4	8	0	4	15	2
660875	1	39	402,000	0	-	4.5	3	0	5	1	14	1	7

738

739 Summary of all maternal and fetal outcomes for each individual pregnancy, including quantitative vRNA burden and semiquantitative
740 histopathology scores.

741

742 Scores are summed scoring for either vRNA levels or histopathology:

743 *RNA copies/mg tissue scoring: 0 = 0; 1-100 = 1; 100-1000 = 2, 1000-10000 = 3, 10000-50000 = 4.

744 Histopathology scoring: 0 = normal; 1 = minimal; 2 = mild; 3 = moderate; 4 = severe.

745 MFI = maternal-fetal interface (aggregate of decidua, placenta, amniotic and chorionic membranes)

746 **SUPPLEMENTARY FIGURES:**

747

748 **Supplementary Figure S1.** Comprehensive sampling experimental timeline for pregnant
749 animals in the current study. Each animal in the study is indicated at the left, color blocks
750 represent when specific samples were collected (e.g., CSF on 43 dpi (81 days gestation) for
751 animal 827577).

752

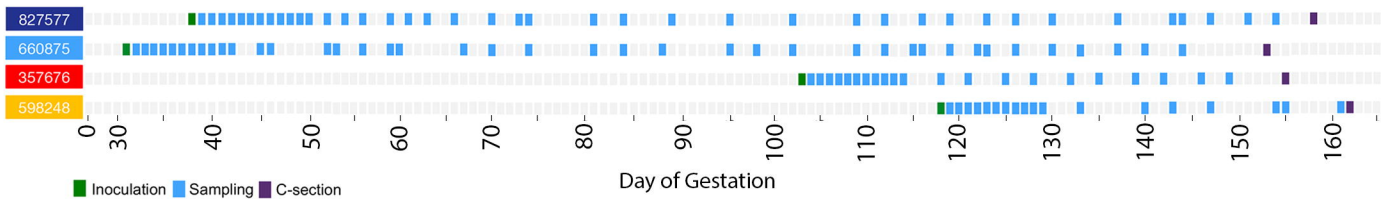
753 **Supplementary Figure S2.** Fetal brain imaged by MRI in ZIKV-infected pregnancies. (A) T2-
754 weighted axial images of the fetus from dam 660875 at 60 dpi (91 days gestation) acquired with
755 a single shot fast spin echo (SSFSE) sequence. Fluids such as the intraocular fluid, CSF, and
756 amniotic fluid as well as fat appear bright on these images. The brain anatomy appears normal.
757 (B) The same fetus acquired with a multiecho spoiled gradient echo sequence.

758

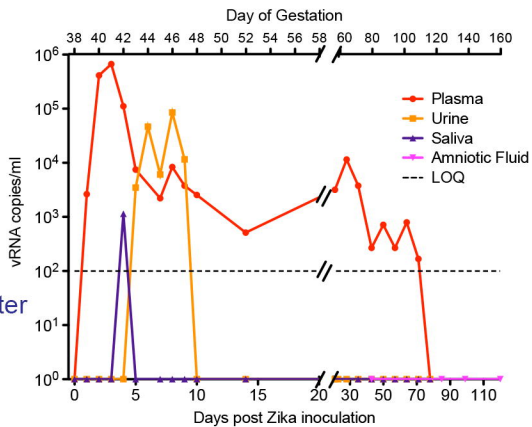
759 **Supplementary Figure S3.** Descriptive diagram showing all maternal and fetal tissues that
760 were sampled at collection.

761

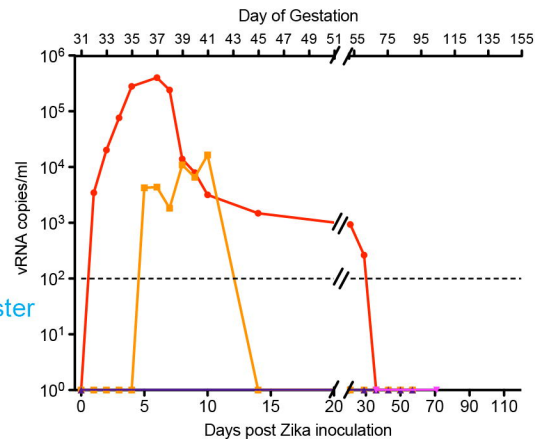
762 **Supplementary Data S1.** Morphologic diagnoses from gross and histologic examination of
763 maternal, fetal, and maternal-fetal interface tissues.

A**B**

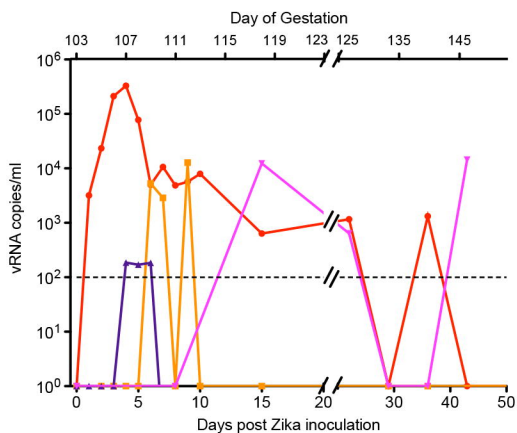
827577
1st trimester



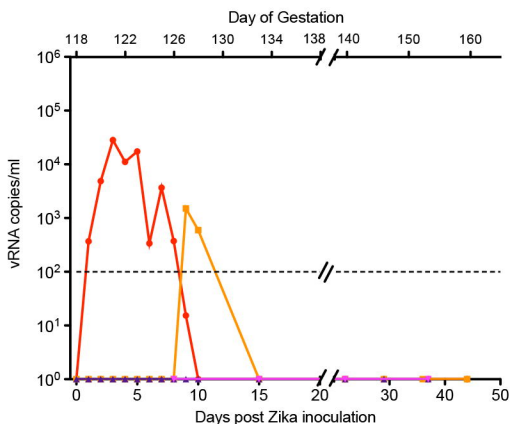
660875
1st trimester

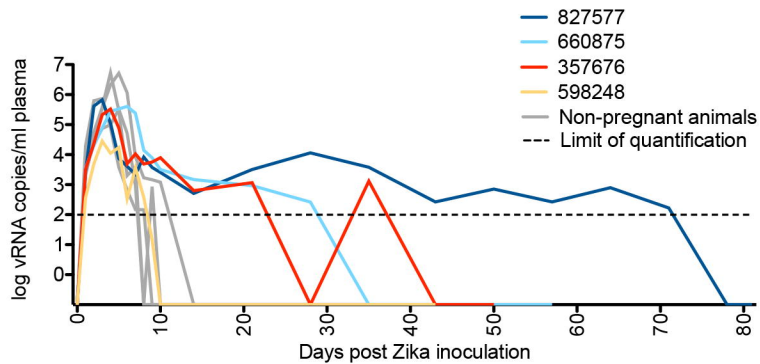
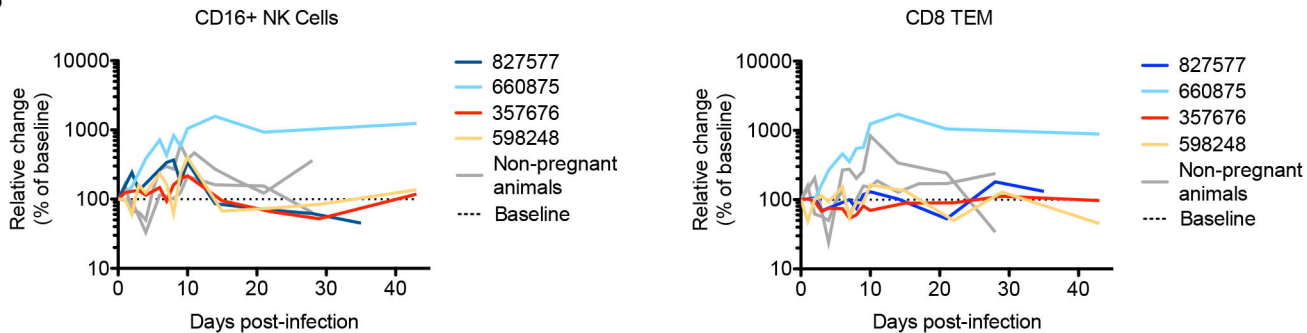
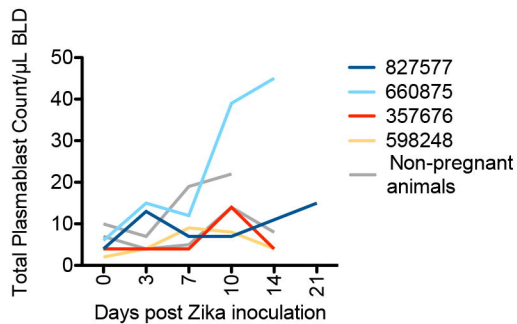
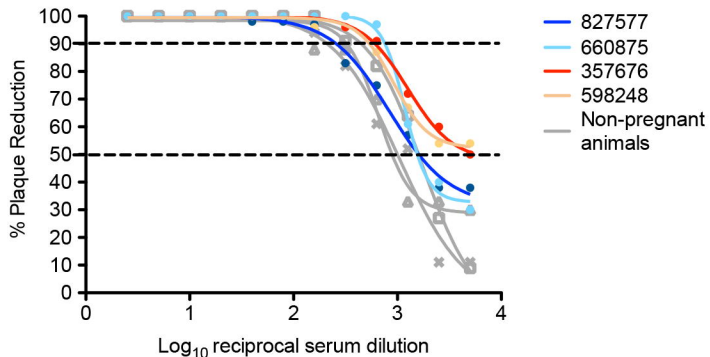


357676
2nd/3rd
trimester



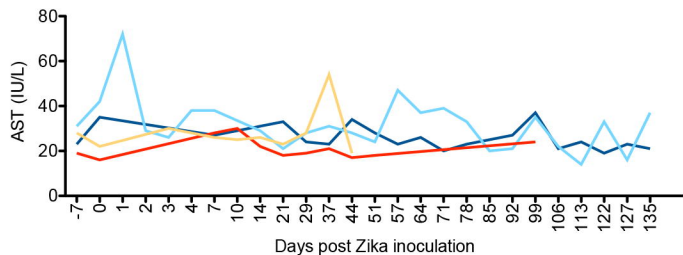
598248
2nd/3rd
trimester



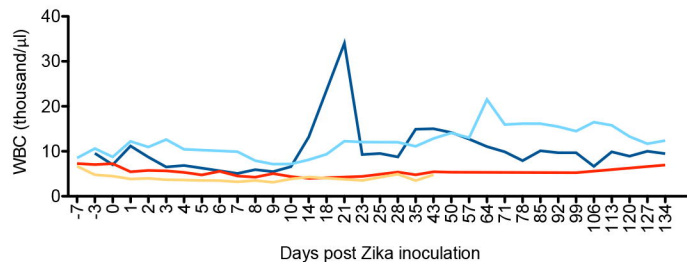
A**B****C****D**



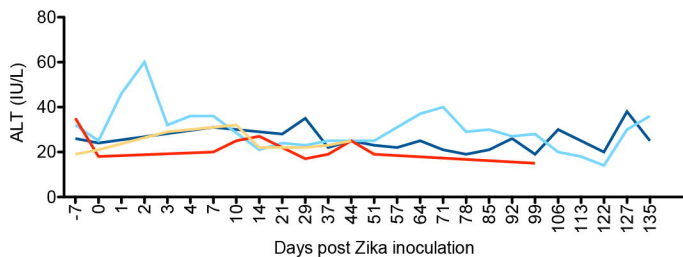
B



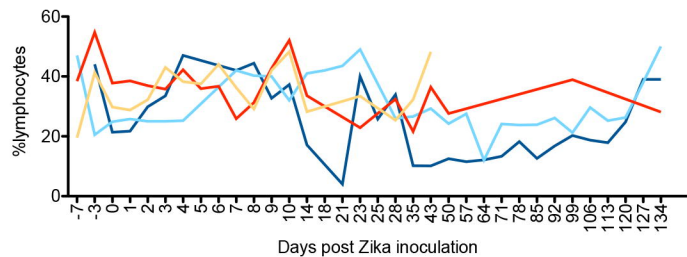
E



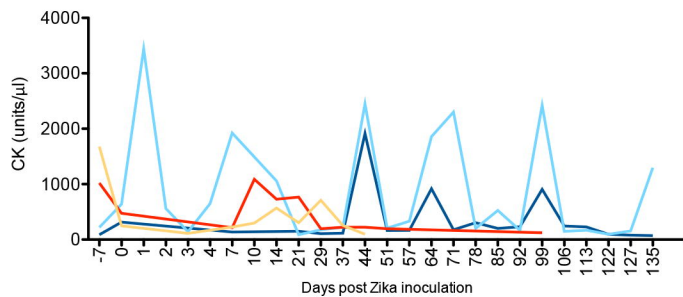
C



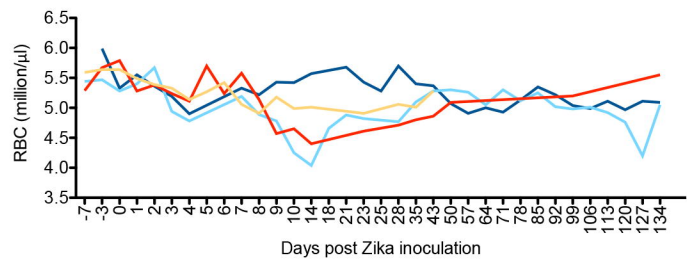
F

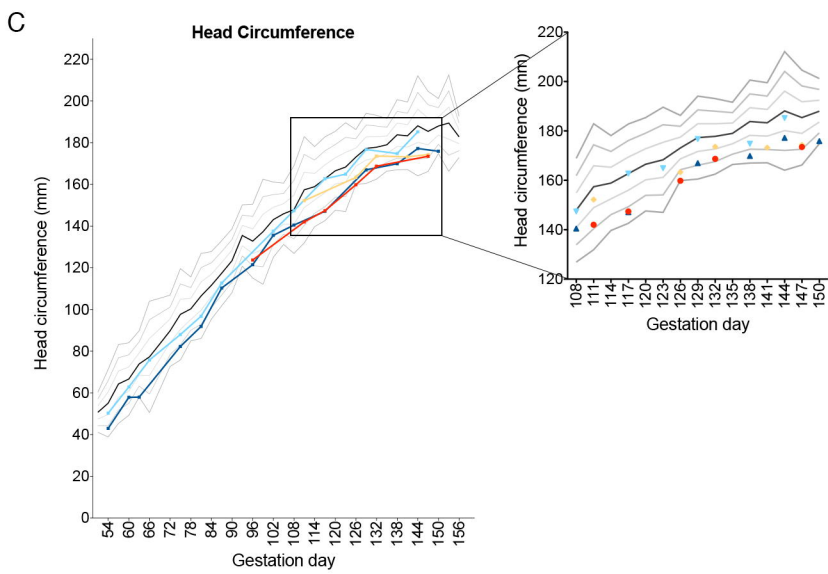
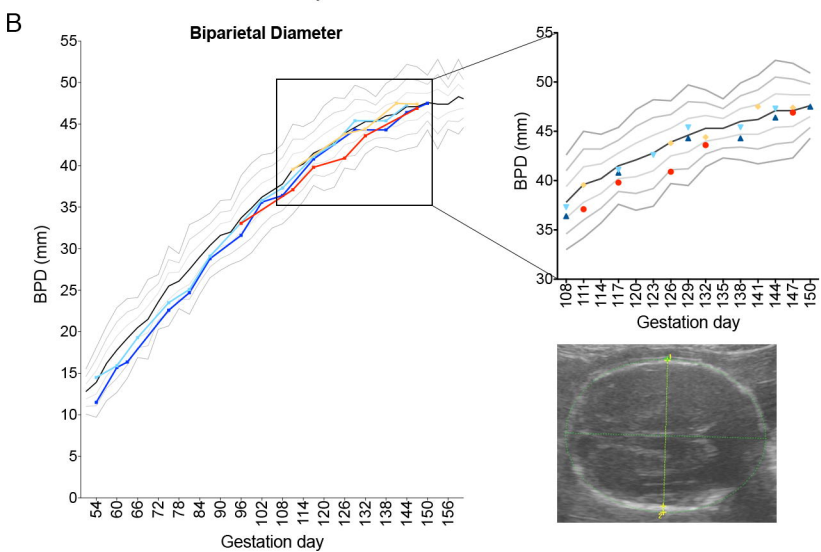
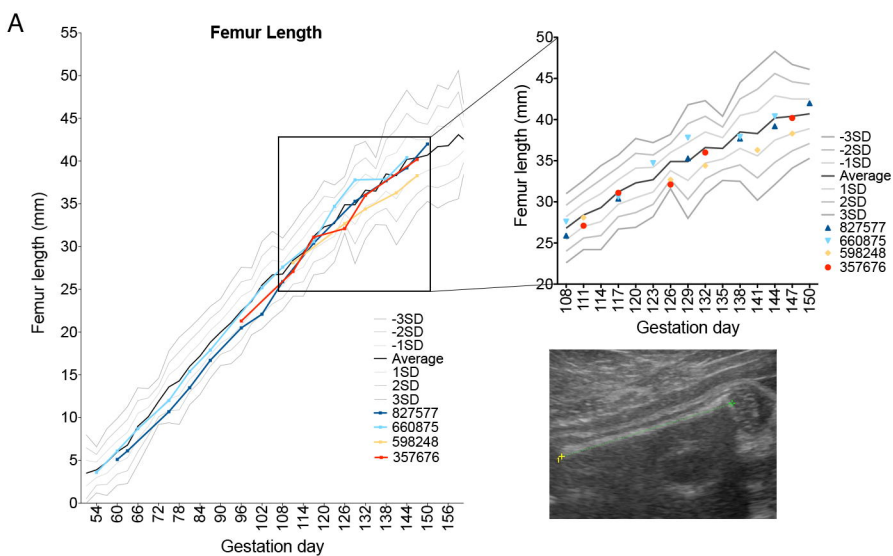


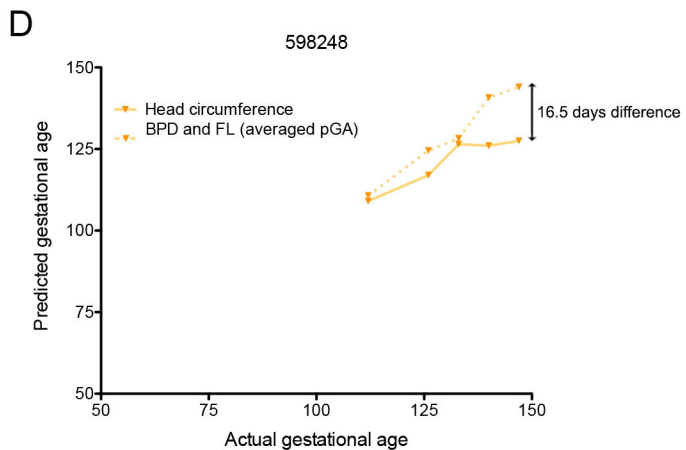
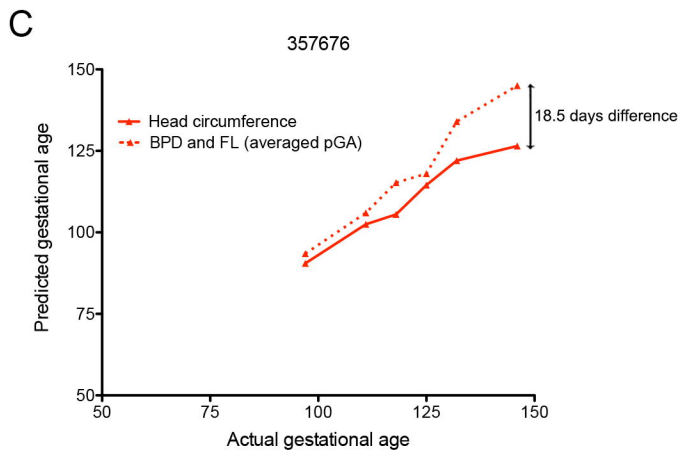
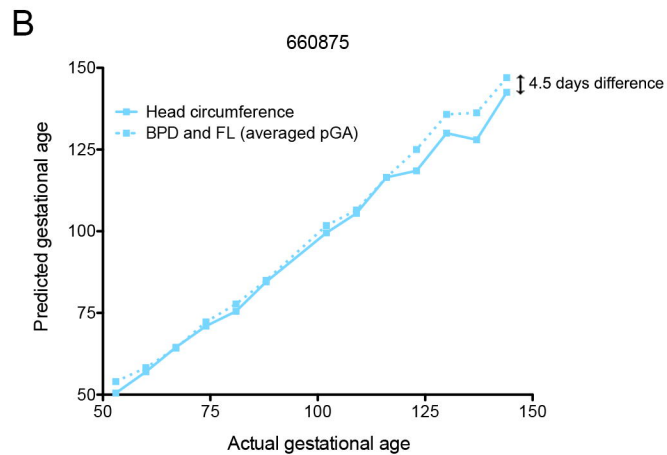
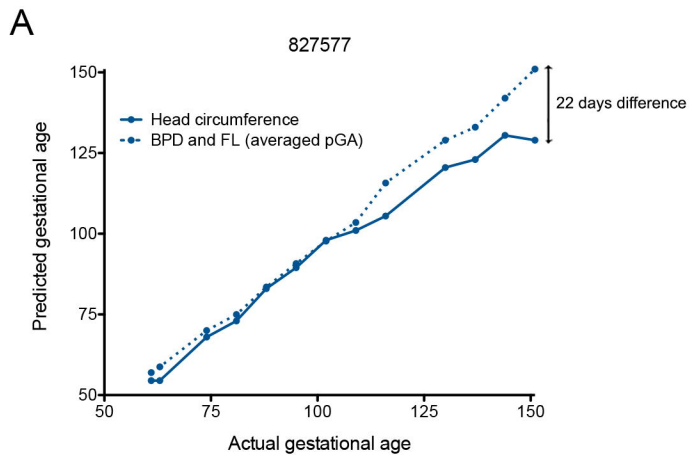
D





G









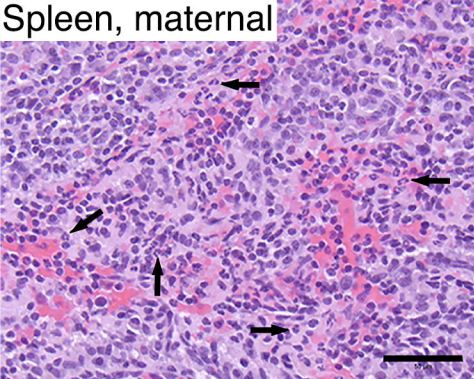
A



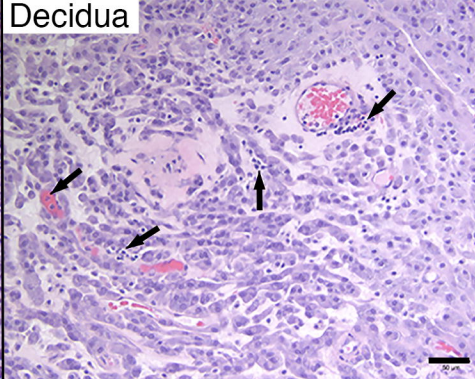
B



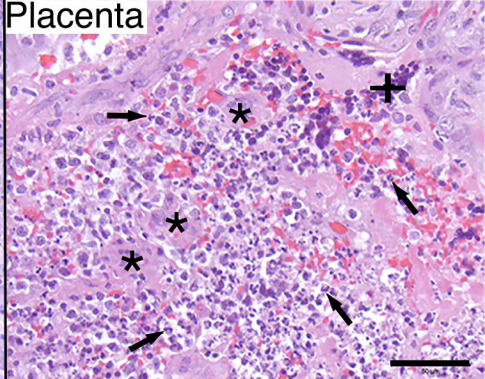
Spleen, maternal



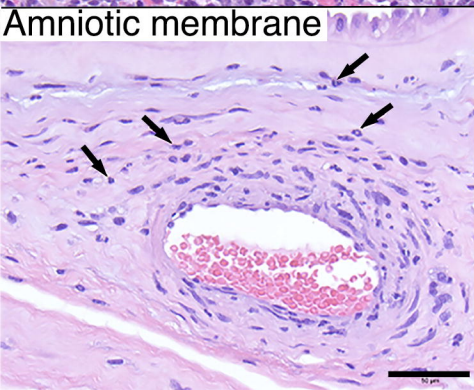
Decidua



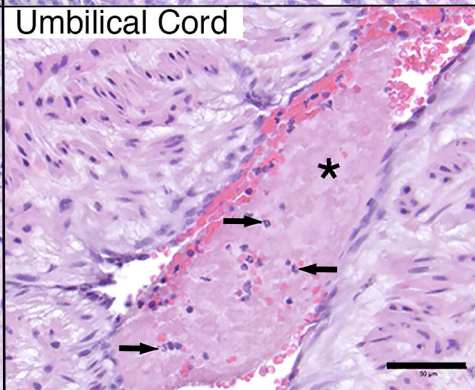
Placenta



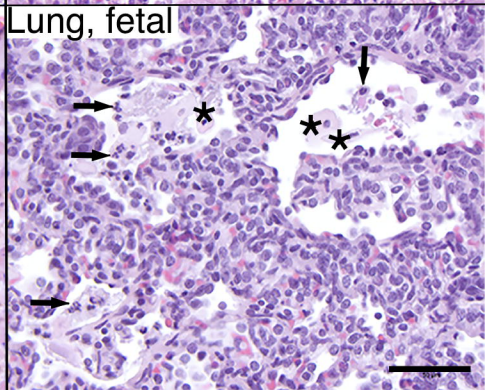
Amniotic membrane



Umbilical Cord



Lung, fetal



660875
1st trimester



827577
1st trimester



357676
2nd/3rd trimester



598248
2nd/3rd trimester

